

Rubberdam Clamp Ingestion During Root Canal Treatment: A Case Report

Ece ÇALIŞKAN¹

Hafız HANDE GÜRBÜZ²

Rüştü DAĞLAROĞLU³

Raif ERİŞEN⁴

Abstract

Foreign body ingestion and aspiration is probably one of the most serious accidents that may occur during root canal treatment. To prevent such a danger, rubber dam isolation is mandatory. Clinically, when a foreign body is ingested, the results may vary from esophageal or gastric ruptures to peritonitis or even death. This article presents a case of rubber dam clamp ingestion during the endodontic treatment of lower right second molar. 51-year old male patient experienced a feeling of obstruction and pain in the esophageal region; he was immediately presented to otolaryngology department. Posteroanterior chest graphy showed the foreign body in esophagus. Clamp was removed under general anesthesia via esophagoscope and patient was hospitalized for 4 days.

Keywords: *rubber dam, foreign body ingestion, case reports*

Özet

Herhangi bir yabancı cismin aspirasyonu veya yemek borusuna kaçması, kanal tedavisi sırasında olabilecek en önemli ve talihsiz kazalardandır. Bunu önlemek için ‘rubber dam’ kullanmak çok önemlidir. Yabancı cisim, özofagustan veya gastrointestinal sistemden geçerek peritonite sebep olabilir hatta ölüme yol açabilir. Bu vaka raporunda hastanın alt sağ 2. Büyük azı dişine yapılan kanal tedavisi sırasında; rubber dam klambini yutması sunulmuştur. 51 yaşında erkek hasta, kanal tedavisinden sonra; özofagus bölgesinde ağrı ve tıkanma hissiyle Kulak Burun Boğaz Hastalıkları Bölümüne başvurmuştur. Alınan göğüs radyografisinde, hastanın yuttuğu yabancı cismin özofagusunda olduğu gözlenmiştir. Özofagusta bulunan rubber dam klambi, genel anestezi altında alınmış ve hasta 4 gün müşadedede kalmıştır.

Anahtar Kelimeler: *rubber dam, yabancı cisim yutulması, vaka raporları*

¹ (DDS, PhD) İstanbul Aydın Üniversitesi Diş Hekimliği Fakültesi Endodonti Anabilim Dalı, Corresponding Author: ececaliskan@aydin.edu.tr

² (DDS) İstanbul Üniversitesi Diş Hekimliği Fakültesi Endodonti Anabilim Dalı

³ (DDS, PhD) İstanbul Üniversitesi Diş Hekimliği Fakültesi Endodonti Anabilim Dalı

⁴ (DDS, PhD) İstanbul Üniversitesi Diş Hekimliği Fakültesi Endodonti Anabilim Dalı

Introduction

Even in the hardest cases of endodontics, rubberdam isolation was made obligatory since 1994 by European Society of Endodontology.¹ Without its application, the tooth may be contaminated with saliva or the patient may swallow irrigants.² In the worst case scenario, the patient may aspirate or ingest endodontic instruments. A study in french population showed that between the years 1994 and 2004, 44 cases of aspiration and 464 cases of ingestion had been reported by general practioners.³

Accidentally ingested foreign bodies present emergencies and should be taken care by an otolaryngologist, gastroenterologist or a general surgeon.⁴ In the dental practice, most of the objects we use are sharp and cornered, which raises the risk of perforation.⁵ Files and broaches carry this high risk. Rubber dam clamps are multi-cornered and relatively large objects, hence their perforation risk is very low. Such objects are expected to exit the gastro-intestinal canal atraumatically in 4 days-2 weeks.⁶ Sharp and angled instruments generally lodge in the esophagus and if not removed, they may also get impacted.⁷ Lodging of a foreign body may also result in inflammation and infection. In most of the cases ingested body should be removed surgically.⁷

Objects swallowed by patients mostly consist of endodontic files, broaches, amalgam fillings, burs, temporary crowns and orthodontic bands.³ In this report, we present a rare case of rubber-dam clamp ingestion.

Aim

To emphasize the possible outcomes of foreign body ingestion during root canal treatment.

Case Report

A 51-year old male patient applied to a private clinic in Istanbul. Tooth number 47 showed clinical signs of irreversible pulpitis and the dentist began to perform a root canal treatment. When the dentist tend to place a winged clamp with a carrier, clamp became loose and fell into the mouth near uvula. This incident triggered patient's swallowing reflex and caused the clamp to move in the oropharynx. Together with his assistant he tried to remove it by Heimlich's maneuver, but it didn't help. Then the dentist convinced the patient, that the clamp would uneventfully leave the gastric canal in a couple of days, so he was not supposed to eat solid food during this time, and he was sent home.

A few hours later patient started to experience discomfort and a feeling of obstruction in the upper-chest region and applied to our department for a consultation. We immediately presented the case to the otolaryngology department in our university. After the physical examination the first diagnosis was a foreign body lodging. To determine its location, posteroanterior and lateral chest graphs were taken. The radiographs clearly showed the position of the clamp (Fig.1). The otolaryngologists concluded, that the clamp migrated to the esophagus and it should be taken out.

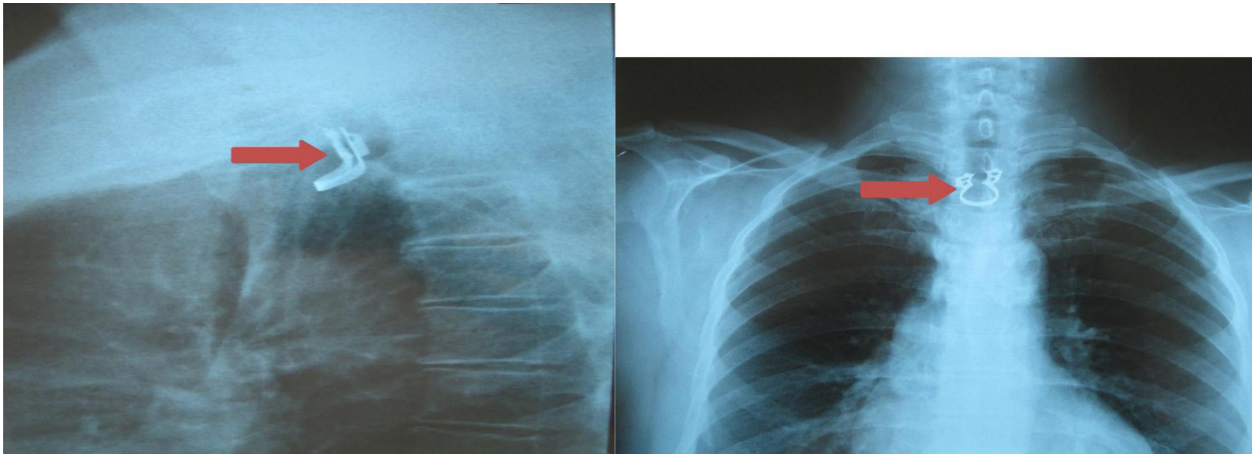


Figure 1. posteroanterior and lateral chest graphs

The next morning, rubber dam clamp was taken out under general anesthesia via esophagoscope (Fig.2). It was precisely located laterally in the first constriction of esophagus. Post-operative findings were normal, but the patient was fed parenterally for 2 days.

On the third day, he was allowed to feed orally and he didn't experience any problems. He was discharged on the fourth day. On the one week follow-up the patient told that, he didn't feel any discomfort and he could feed himself without any problem. The otolaryngologists agreed that he was completely healed and no more follow ups were necessary. The lower right second molar was extracted due to a vertical fracture.



Figure 2. Ingested rubber dam clamp

Discussion

Rubber Dam is used in endodontics to protect the patient from aspiration or ingestion of instruments, tooth debris, medicaments and irrigating solutions. It isolates the operating field from saliva, hemorrhage, other tissue fluids as well as oral cavity. So it reduces the risk of cross-contamination of root canal system.

A dentist must carefully follow every step of rubber dam placement procedure. Improper clamp selection or careless placement of the clamp may result in serious complications as in our case.

REFERENCES

- [1] European Society of Endodontology. Consensus report of the European Society of Endodontology on quality guidelines for endodontic treatment. *Int Endod J* 1994;27,115-24.
- [2] Ahmad IA. Rubber dam usage for endodontic treatment: a review. *Int Endod J* 2009;42,963–72.
- [3] Susini G, Pommel L, Camps J. Accidental ingestion and aspiration of root canal instruments and other dental foreign bodies in a French population. *Int Endod J*. 2007;40,585–9.
- [4] Saha S, Bose A. Perils of Prolonged Impaction of Oesophageal Foreign Bodies. *ISRN Surg* 2011 ; ;2011:621682. doi: 10.5402/2011/621682
- [5] Tiwana KK, Morton T, Tiwana PS. Aspiration and ingestion in dental practice: a 10-year institutional review. *J Am Dent Assoc* 2004 ;135:1287-91.
- [6] Govila CP. Accidental swallowing of an endodontic instrument. A report of two cases. *Oral Surg , Oral Med , Oral Pathol* 1979;48, 269–71.
- [7] Sarah L.W. Sperry, BA, Seth D. Crockett, MD, MPH, C. Brock Miller, MD, Nicholas J. Shaheen, MD, MPH, Evan S. Dellon, MD, MPH Esophageal foreign-body impactions: epidemiology, time trends, and the impact of the increasing prevalence of eosinophilic esophagitis. *Gastrointest Endosc* 2011;74:985-91.