



Aydın Dental Journal

Journal homepage: <http://dergipark.ulakbim.gov.tr/adj>



TREATMENT OF SKELETAL CLASS II DIVISION II MALOCCLUSION WITH ACTIVATOR AND FIXED ORTHODONTIC APPLIANCES: A CASE REPORT

DergiPark
AKADEMİK

Sanaz SADRY PhD DDS¹, Fatma BURSALI PhD DDS², Nourtzan KECHAGIA DDS²

ABSTRACT

The aim of this case report; is to present the treatment of a male patient with skeletal Class II, dental Class II division II associated with deep bite by the using of functional appliance through a short period of fixed orthodontic treatment. A 14-year 4-month old male patient applied for treatment in our clinic with a chief complains of retrognathic mandible. The radiographic and clinical examinations and evaluations showed skeletal class II anomalies. Dental class II division II anomaly with increased over bite had been identified. The orthodontic treatment started with functional appliance as activator. After 8 months mandibular advanced and Class I molar and canine relationship had been achieved. after

functional treatment 0.018 slot straight wire Roth brackets applied for both the upper and the lower teeth. After 6 months for both jaws a 0.016 x 0.022 stainless steel wire had been applied. After that the intrusion of the incisive teeth had been achieved by using CIA. In order to achieve a Class I molar and canine relationship, Class II elastics had been used at the end of the treatment. A case with a skeletal class II and Dental class II division II with increased over bite was treated through a 2 years and 8 month of treatment and dental class I relationship with normal overbite and overjet and good occlusion achieved at the end of the treatment.

Keywords: *Class II division 2, Deep-bite, Functional therapy, Connecticut intrusion arch (CIA)*

¹ *Istanbul Aydın University Faculty of Dentistry Department of Orthodontics*

AKTİVATÖR VE SABİT ORTODONTİK UYGULAMALARLA İSKELETSEL SINIF II DİVİZYON II MALOKLÜZYONUN TEDAVİSİ: BİR VAKA RAPORU

Dr. Öğr. Üyesi Sanaz SADRY¹, Dr. Dt. Fatma BURSALI¹, Dt. Nourtzan KECHAGIA¹

ÖZ

Bu vaka raporunun amacı; iskeletsel Sınıf II, dişsel Sınıf II divizyon II ve derin örtülü kapanışa sahip olan erkek hastanın fonksiyonel aparey ile kısa süreli sabit ortodontik tedavisini içeren olguyu sunmaktır. Kliniğimize 14 yıl 4 aylık erkek hasta alt çene geriliği ve üst dişlerin şikayetiyle başvurdu. Yapılan klinik ve radyografik değerlendirmede iskelets sınıf II, dişsel sınıf II divizyon II anomali, artmış overbite saptandı. Tedaviye fonksiyonel aparey olan aktivatör ile başlandı. 8 ay sonar mandibuler ilerletme ve sınıf I molar ve kanik ilişkisi sağlandı. Fonksiyonel tedaviden sonar

alt ve üst dişlere 0.018 slotrothstraightwire braketter uygulanarak başlandı. Her iki çenede de 0.016x0.022 paslanmaz çelik arklara 6 ayda geçildi. Daha sonra Connecticut intruzyon arki ile kesici dişlerin intruzyonu gerçekleştirildi. Son olarak sınıf II elastikler kullanıldı. Sonuç olarak dişsel sınıf II divizyon II, artmış overbite olan vakada 18 aylık tedavi sonucunda dişsel sınıf I ilişkilerle birlikte normal overbite ve overjete sahip iyi bir okluzyon sağlanmıştır.

Anahtar Kelimeler: Sınıf II div II, Derin örtülü kapanış, fonksiyonel tedavi, Connecticut intruzyon arki (CIA)

¹Istanbul Aydın Üniversitesi Diş Hekimliği Fakültesi Ortodonti ABD

INTRODUCTION

Skeletal and / or dental class II malocclusions, the most common orthodontic anomaly in the community many researches on this subject to date and clinical trials. Class II closing disorders skeletal and dental can be divided into two subclasses. Skeletal Class II disorders, upper jaw and upper teeth. The head is positioned further than the base, the lower jaw and The lower teeth are positioned behind or two mismatches co-developed¹. Angle classification of orthodontic anomalies is frequently used in the dental classification. According to Angle, it is considered to be a Class II anomaly in relation to the upper first molar, which is more distal to the lower six age teeth². Skeletal II. While orthopedic and orthodontic corrections are targeted before the growth and development of class disorders are completed^{3,4}. can be targeted for surgical approaches^{5,6} or camouflage treatments^{7,8} according to the severity of the disorder after growth and development are completed. Many movable and stationary functional apparatus variants have been designed for the treatment of Class II malocclusions characterized by mandibular insufficiency. Deep-bite jaws are defined as centric occlusion while the upper incisors cover the lower incisor teeth more than the position in the vertical direction⁹. Proportional amount of upper incisor teeth, lower incisor teeth in vertical direction according to profit an average of 1-2 mm¹⁰.

Deep-bite treatment, skeletal malocclusion and dentoalveolar structure may differ¹¹. Deeply covered aesthetic appearance and ideal closure to obtain a closing relationship is required. During the growth of the treatment or taking into account is a condition that should. Many researchers early the severity of malocclusion it will reduce and facilitate treatment^{12,13}.

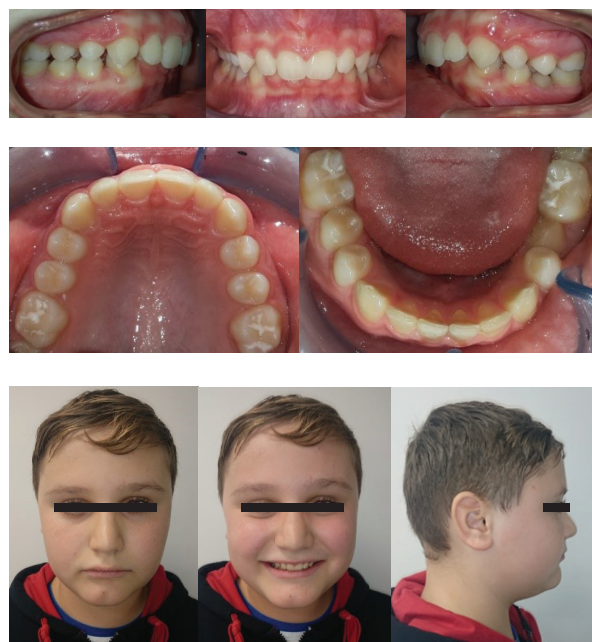

Figure 1: Initial facial and intraoral photographs

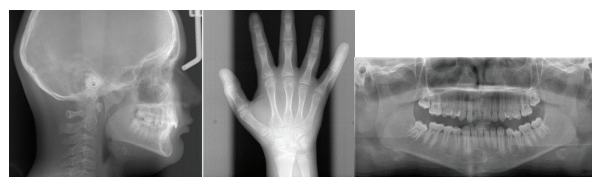


Figure 2: Initial panoramic, cephalometric and hand wrist radiographs.

CASE REPORT

A 14 years and 4 months male patient presented for initial examination at the orthodontic clinic in good general health and no history of serious illness or injury. The chief complaint of the patient was related to the fact that the upper incisors were malpositioned. The patient presented with an Angle Class II, Division II malocclusion, convex profile, 2.5mm overjet and 5.5mm overbite, sharp retroclination of teeth 11,12, 21 and 22 (Fig.1) The hand wrist radiograph showed that the patient was at pre-peak skeletal stage (MP3=) and panoramic radiograph of the patient didn't show any

caries or pathology (Fig.2). The side profile X-ray and cephalometric tracing showed: retruded and retroclined upper incisors ($1-NA=15^\circ$, $1/NA=0\text{mm}$), proclined lower incisors ($1-NB=32$, $IMPA=103$), Class II skeletal pattern with mandibular retrognathie, ANB angle= 4.5° , ($SNA=80^\circ$ and $SNB=75.5^\circ$) and normal mandibular growth in the vertical orientation ($SN-GoGn=29^\circ$, $FMA=27^\circ$ and $Y\text{-axis}=62^\circ$). A facial evaluation showed normal lower lip and protruded positioned upper lip. A treatment plan was established, starting with a aktivator functional appliance, with the aim to stimulate the growth of the mandible, which included an upper anterior screw for the correction of the retruded upper incisors. The monoblock appliance with anterior screw was employed with activation of $2/4$ turn of the screw once a day and has an acrylic cap for the lower incisors to provide retroclination. The appliance was reactivated after the proclination of upper incisors and mandibular growth was stimulated after total 16 month of monoblock treatment with the correction of the molar and canine relationship and space for tooth alignment (Fig 3). After functional treatment fixed orthodontic treatment was started by applying 0.018 slot roth straight twire metal brackets to the lower and upper teeth. Both jaws were passed to 0.016×0.022 stainless steel arches in 5 months. Although the teeth were leveled a little overbite was reduced, and then the Connecticut intrusion arc was applied to the lower and upper teeth. In order to prevent protruding of the cutters and to prevent the wire from sliding forward, the arc wires are curled sharply from the distal of the molars. Class I molar and canine relationship were also achieved with class II elastics after intravenous incision. After ensuring that all the intended goals had been achieved, the fixed orthodontic appliance was removed

and the retention phase begun. Fixed lingual retainers were bonded canine to canine on upper and lower arch and essix retainers were applied (Fig 4). As a result of dental grade II subdivision, increased overbite in the case of 2 years and 8 months of treatment as a result of dental class I relationships with normal overbite and overexpression has been achieved a good.

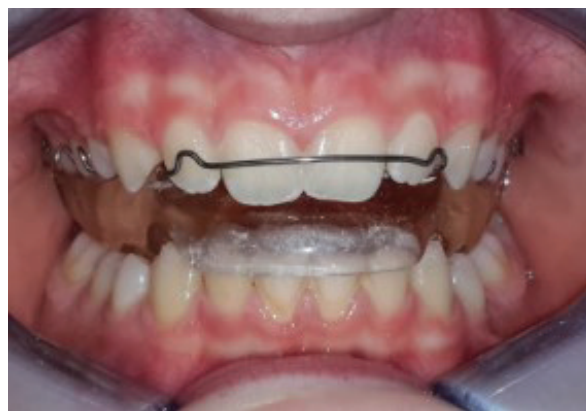

Figure 3: The Monoblock appliance and the reactivation after upper

DISCUSSION

Class II malocclusion might have any number of a combination of skeletal and dental component. Hence, identifying and understanding etiology and expression of Clas II malocclusion and identifying differential diagnosis helpful for its correction and to select treatment planning whether functional, orthodontic or surgical¹⁶. When the treatment of class II division II malocclusion, which results in a relapse of treatment at later ages, is done early, positive results can be obtained. Aktivator is a functional appliance that has been used for many years and is effective in correcting class II division II malocclusion with inserting a screw in the frontal area of the appliance for porclinations of retruded upper incisors. Patient can wear appliance full time with little discomfort. It is suitable for mixed

dentition as well as deciduous dentition. There were several studies where they have documented the ability of activator to produce significant skeletal as well as dentoalveolar changes which in combination correct Class II malocclusion^{17,18}. Deep-bite closure, defined as the incision of the incisors by the normal amount of the teeth in the vertical direction, is an important problem and this amount has been specified by different researchers starting from 3 mm to 5 mm and above^{19,20,21}. When the incision of the incisors as a treatment plan is considered in the treatment of deep vein closure, intrusive arches and mini implants are among the treatment options^{22,23}.

In this case, comparison of pre-treatment and post-treatment lateral cephalogram showed SNA remained unchanged, and SNB increased by 80°. ANB angle reduced up to 0°. Retroclination of maxillary incisors is corrected and length of the mandible is increased by 6mm.

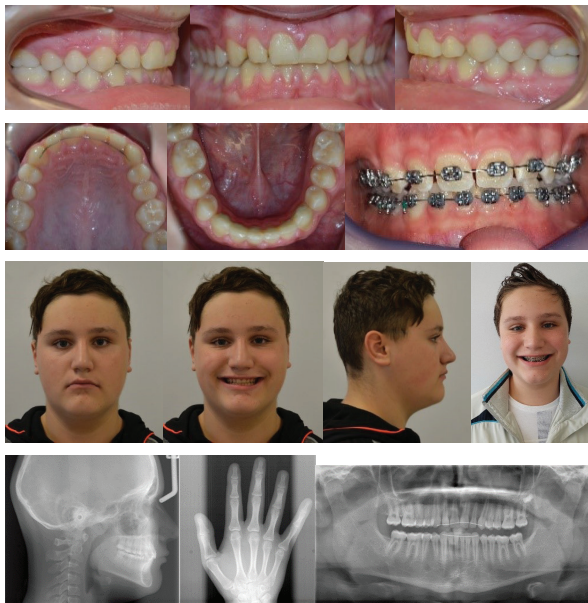

Figure 4: Final facial and intraoral photographs and final radiographs.

Table 1: Orthodontic Measurements of the patient

Sagittal	NORMAL	T1	T2
SNA	82° ± 2	80	80
SNB	80° ± 2	75,5	80
ANB	2° ± 2	4,5	0
N-A	0 ± 3	0	0
N-PG	-4 ± 5	-3	-3,5
Witts	-1 ± 3	4	0
SN-GOME	32° ± 7	29	29
FMA	25° ± 5	24	23
N-ME	114.4 ± 5	104	110
Ef.middle face (CO-A)	78	82	78
Ef.mand.(CO-GN)	95-97	104	110

CONCLUSION

As a result, this case report shows the effect of the functional appliance as activator for advancement of mandible depends on patient cooperation and case selection. The use of this device in the growing phase with good patient cooperation creates a positive skeletal and dentoalveolar effect. Intrusion of the incisors with the Connecticut intrusion arc; low cost and non-invasive advantages as well as successful results can be taken.

KAYNAKLAR

- [1] Acar Güngör A. Sınıf II maloklüzyonların tedavisinde molar distalizasyonu. EÜ Dişhek Fak Derg 2006;27:97-105.
- [2] Ast DB, Alaway M, Darker HL. The prevalence of malocclusion, related to dental caries and lost first permanent molars, in a fluoridated city and a fluoride deficient city. Am J Orthod 1962;48:106-13.

- [3] Vargervik K, Harvold EP. Response to activator treatment in class II malocclusions. *Am J Orthod* 1985; 88: 242-251.
- [4] Arvystas MG. Nonextraction treatment of severe class II, division 2 malocclusions. *Am J Orthod Dentofacial Orthop* 1991; 99: 74-84.
- [5] Epker BN, Fish CF. The surgical-orthodontic correction of mandibular deficiency. Part I. *Am J Orthod* 1983; 84: 408-21.
- [6] Epker BN, Fish CF. The surgical-orthodontic correction of mandibular deficiency. Part II. *Am J Orthod* 1983; 84: 491-507.
- [7] Harnick DJ. Case report: Class II correction using a modified Wilson bimetric distalizing arch and maxillary second molar extraction. *Angle Orthod* 1998; 68: 275-280.
- [8] Bishara SE. *Textbook of orthodontics*. 1st Ed., Saunders, Philadelphia, USA, 2001, 354-361.
- [9] Graber TM, Vanorsdall R, Vig K. 2000. *Orthodontics: Current Principles and Techniques*, Third Edition. St. Louis, Toronto, London: The C.V. Mosby. Comp.
- [10] Proffit WR, Fields HW, Ackerman JL, Bailey LJ, Tulloch JFC. 2000. *Contemporary Orthodontics*, Third Edition. St. Louis, Toronto, London: The C.V. Mosby Comp.
- [11] Graber T. 1997. *Functional Analysis*. Graber T, Petrovic A, (Ed.). *Dentofacial Orthopedics with Functional Appliances*, pages, 125-160. Baltimore, Boston: Mosby-Year Book, Inc.
- [12] Engel G, Cornforth G, Damerell JM, Gordon J, Levy P, McAlpine J. et al. 1980. Treatment of deep-bite cases. *Am J Orthod*, 77(1): 1-13.
- [13] Arvystas MG. 1990. Nonextraction treatment of severe class II, division 2 malocclusions. Part 1. *Am J Orthod Dentofacial Orthop*, 97(6): 510-521.
- [14] Bishara SE, Jamison JE, Peterson LC, DeKock WH. 1981. Longitudinal changes in standing height and mandibular parameters between the ages of 8 and 17 years. *Am J Orthod*, 80(2): 115-135.
- [15] Engel G, Cornforth G, Damerell JM, Gordon J, Levy P, McAlpine J. et al. 1980. Treatment of deep-bite cases. *Am J Orthod*, 77(1): 1-13.
- [16] Sharma NS. Management of growing skeletal class II patient: A case report. *Int J Clin Paediatr Dent* 2013; 6:48-54.
- [17] Dağsuyu ĞM. Sınıf II Bölüm 1 maloklüzyonlu bireylerde fonksiyonel ortopedik tedavi etkilerinin aksiyografik ve sefalometrik yöntemlerle incelenmesi. *J Dent Fac Atatürk Uni* 2011; 21:196-212.
- [18] Özel N AA. Sınıf II maloklüzyonların tedavisinde kullanılan fonksiyonel ortopedik apareyler. *Smyrna Tıp Dergisi* 2011:48-52
- [19] Nanda R. 2005. Management of Deep Overbite Malocclusion (chapter 7). *Biomechanics and esthetic strategies in clinical orthodontics*: Elsevier inc.
- [20] Tausche E, Luck O, Harzer W. 2004. Prevalence of malocclusions in the early mixed dentition and orthodontic treatment need. *Eur J Orthod*, 26(3): 237-244.
- [21] Burstone CR. 1977. Deep overbite correction by intrusion. *Am J Orthod*, 72(1): 1-22.
- [22] Kim TW, Kim H, Lee SJ. 2006. Correction of deep overbite and gummy smile by using a mini-implant with a segmented wire in a growing class II division 2 patient. *Am J Orthod Dentofacial Orthop*, 130(5): 676-685.